

## CASE STUDY

## ACUTE PULMONARY EMBOLISM BY AMNIOTIC FLUID – A RARE COMPLICATION OF PERINATAL PERIOD THAT SHOULD NOT BE FORGOTTEN

DOI: 10.36740/WLek202108139

Mateusz Jermakow<sup>1</sup>, Agnieszka Palus<sup>2</sup>, Michał Ciużyński<sup>1</sup>, Bronisława Pietrzak<sup>3</sup>, Katarzyna Kurnicka<sup>1</sup>, Piotr Pruszczyk<sup>1</sup>, Piotr Bienias<sup>1</sup>

<sup>1</sup>DEPARTMENT OF INTERNAL MEDICINE AND CARDIOLOGY, MEDICAL UNIVERSITY OF WARSAW, WARSAW, POLAND

<sup>2</sup>STUDENTS' SCIENTIFIC ASSOCIATION BY DEPARTMENT OF INTERNAL MEDICINE AND CARDIOLOGY, MEDICAL UNIVERSITY OF WARSAW, WARSAW, POLAND

<sup>3</sup>1ST DEPARTMENT OF OBSTETRICS AND GYNECOLOGY, MEDICAL UNIVERSITY OF WARSAW, WARSAW, POLAND

### ABSTRACT

Amniotic fluid embolism (AFE) is a diagnostically challenging type of pulmonary embolism that occurs when amniotic fluid enters maternal circulation during delivery or postpartum. This obstetric complication is very rare but characterized by high mortality rate. The main symptoms are dyspnea, cardiovascular collapse, disseminated intravascular coagulation (DIC) and even sudden cardiac death.

**The aim** of the article is to draw attention to AFE as a rare but possible and catastrophic complication of perinatal period. The authors present a 28-year-old woman who was admitted to obstetric ward during the first stage of labour. The patient developed sudden deterioration of her medical state with acute respiratory distress symptoms. An emergency cesarean section was performed, complicated by excessive bleeding. After a detailed assessment of the patient's condition and evaluation of the results of additional tests, we diagnosed AFE as the cause of the patient's deterioration.

**Conclusions:** The case study shows how unpredictable, unpreventable and dangerous is AFE. It is still one of the main causes of maternal deaths in developed countries. Four diagnostic criteria proposed by the Society for Maternal-Fetal Medicine (SMFM) may accelerate diagnosis. AFE as a medical emergency, requires immediate multidisciplinary response and aggressive treatment. The initial medical care may be facilitated by the application of the general guidelines recommended by SMFM. The case report also emphasizes the need for further research on this disease, in particular on early detection and prevention.

**KEY WORDS:** amniotic fluid embolism, pregnancy complications, disseminated intravascular coagulation, respiratory insufficiency

Wiad Lek. 2021;74(8):2011-2015

### INTRODUCTION

Pregnancy is time in a woman's life when her organism is subject to numerous adaptations in order to prepare for a new role. All these modifications progress throughout gestation [1, 2]. Especially dynamic changes of the female body occur during labour. Sometimes they are accompanied by very intense symptoms. Normal parturition is a generally harmless process and does not require medical intervention. However, when complications occur, there is an imminent danger to the health and life of the mother and the fetus [3]. Sudden deterioration of the patient's state during this period requires aggressive intervention with stabilization of medical condition. One of the very rare and diagnostically challenging complications in the perinatal period is amniotic fluid embolism (AFE).

It occurs when amniotic fluid enters the maternal systemic circulation during delivery or postpartum [4]. This triggers a cascade of reactions that leads to symptoms such as dyspnea, cardiovascular collapse, disseminated intravascular coagulation (DIC) and even sudden cardiac death. Formerly, it was believed that the fetal material contained in the amniotic fluid physically obstructs the mother's pul-

monary circulatory system. Recently, it is hypothesized that this occurs due to the abnormal activation of the mother's immune mechanisms after the fetal antigens enter maternal circulation. Altogether, the exact pathological mechanism is still not fully understood [5-9].

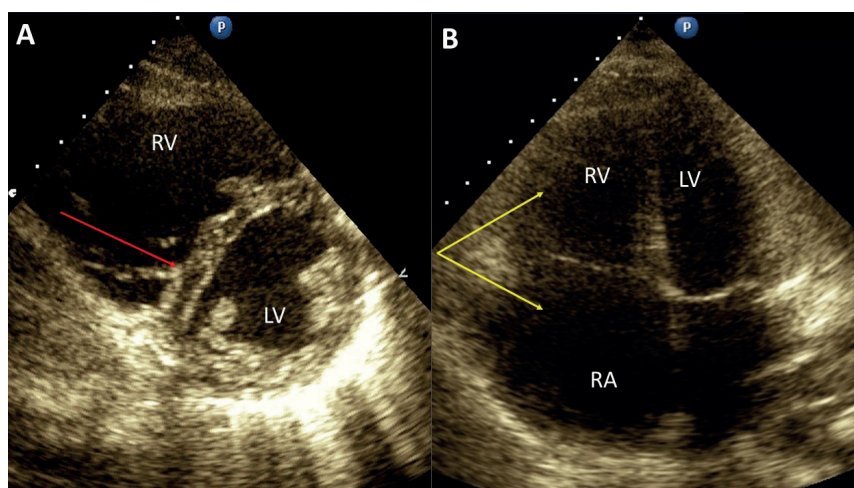
### THE AIM

The aim of the article is to draw attention to AFE as a rare but possible and catastrophic complication of perinatal period.

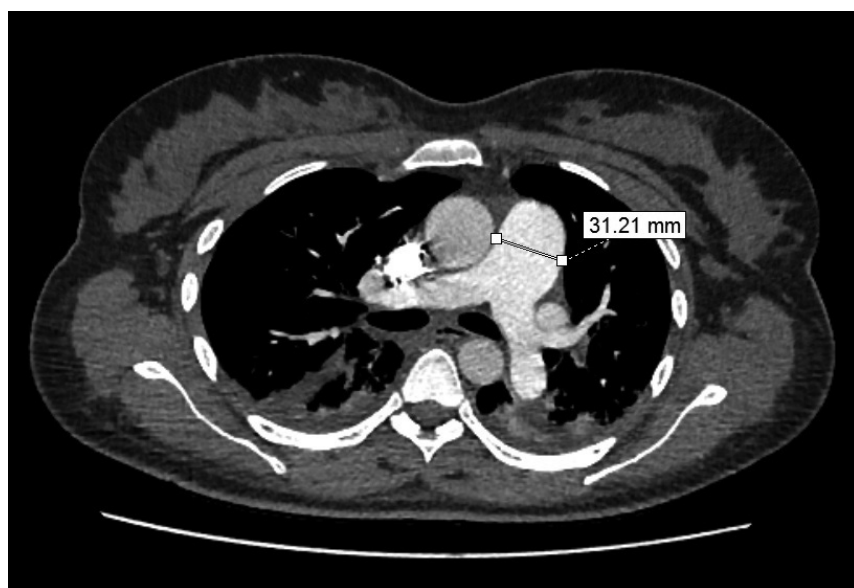### CASE REPORT

A 28-year-old woman in her first pregnancy was admitted to the obstetric ward at 37<sup>+5</sup> weeks of gestation in the first stage of labour. She was in good general condition, also her medical history did not reveal any chronic diseases or burdens. There were no complications during the entire pregnancy, therefore, it was decided to perform vaginal delivery.

However, shortly after insertion of the intrathecal catheter and administration of anesthetics, a rapid deterioration of maternal condition with acute respiratory distress symp-



**Fig. 1.** Echocardiographic signs of the right heart pressure overload. Chart A: Enlarged right ventricle (RV) and flattened interventricular septum (red arrow), short axis view; Chart B: Enlargement of the right ventricle (RV) and the right atrium (RA) (yellow arrows), reduced left ventricle (LV), four chamber view.



**Fig. 2.** Computed tomography pulmonary angiogram. Dilated pulmonary trunk (31.2 mm; normal value 27 mm in females) and both pulmonary arteries. No obvious signs of proximal thrombosis. Mild bilateral pleural effusion.

toms occurred (acute dyspnea, desaturation 92%, low blood pressure 80/50 mmHg, sinus tachycardia 120 bpm). Rapid administration of intravenous fluids and proper oxygenation were provided. The course of subsequent events was very rapid. The epidural anesthesia was applied at the stage of 4 cm dilation, and the amniotic fluid passed out during application of the epidural. At the time of circulatory and respiratory disorders of the mother, the fetus developed bradycardia up to 60 beats per minute. After the patient's condition improved and due to imminent fetal asphyxia, an urgent caesarean section was performed. The newborn was delivered in critical condition, assessed of 1-3-4-4 points in Apgar score in 1-3-5-10 minute, respectively. Cord blood gas had the following parameters: pH 6.8, base excess uncountable, lactates -11.7 mmol/l. After birth, 5 relaxation breaths and an assisted ventilation with  $\text{FiO}_2$  max 0.4 were applied. In the neonatal intensive care unit he was intubated and mechanically ventilated. Fetal amplitude-integrated electroencephalography showed several abnormalities. After 2 hours from birth, a decision was made to use therapeutic hypothermia, which was carried out for 3 days. Mechanical ventilation was continued for

next 2 days and the circulatory system was supported with a continuous intravenous infusion of dobutamine.

During the surgery, excessive bleeding from the woman's wounds was observed, which led to significant blood loss. Moreover, the labour was complicated by uterine atony. The laboratory tests showed previously absent thrombocytopenia ( $67 \times 10^9/l$ ), low fibrinogen (<50 mg/dl) and significantly elevated D-dimer (6300  $\mu\text{g/l}$ ), what could indicate acute DIC (detailed results in Table I). Due to anaemia, the patient received a transfusion of packed red blood cells. Fresh frozen plasma, prothrombin complex concentrate and fibrinogen were also administered, achieving effective hemostasis and normalization of coagulation parameters.

After stabilization of patient's medical condition, a cardiological consultation with echocardiography were performed. Transthoracic echocardiography revealed signs of acute right heart chambers overload (Fig. 1, Table II), possibly due to sudden occlusion of pulmonary arteries. The patient was urgently referred to the cardiac invasive care unit. On admission, she was in serious but stable condition. The woman still suffered from dyspnea at rest due to hypoxemic respiratory failure that responded well

**Table I.** Blood tests results during sudden deterioration of patients' medical state with acute respiratory distress symptoms (worst results chosen).

Parameter (normal value)	Test result
Haemoglobin (12.0-15.5 g/dl)	7.8 g/dl
Platelet (150-450 G/l)	67 G/l
Prothrombin time (9-12 s)	21.9 s
Activated partial thromboplastin time (29-40 s)	51.4 s
Thrombin time (10-16 s)	40.7 s
Fibrinogen (210-358 mg/dl)	<50 mg/dl
D-dimer (<500 mg/dl)	6 300 mg/dl
High-sensitivity troponin T (<14 ng/l)	1 690 ng/l
N-terminal pro-B-type natriuretic peptide (<125 pg/ml)	8 636 pg/ml
Creatinine (0.6-1.3 mg/dl)	2.48 mg/dl

**Table II.** Selected transthoracic echocardiographic parameters.

Parameter (normal value)	Value
Right ventricle diastolic diameter, RVDD (21-35 mm)	45 mm
Left ventricle diastolic diameter, LVDD (35-56 mm)	38 mm
Tricuspid regurgitation peak gradient, TRPG (<30 mmHg)	27 mmHg
Right ventricle systolic pressure, RVSP (<35 mmHg)	37 mmHg
Pulmonary velocity acceleration time, ACT (>105 ms)	94 ms

to passive oxygen therapy 6 liter per minute by a simple face mask. Additional laboratory tests revealed features of acute myocardial and kidney injury (Table I).

Due to significant suspicion of acute pulmonary embolism, an IV bolus of 2500 U unfractionated heparin was administered and computed tomographic (CT) pulmonary angiography was performed, which did not reveal thrombi in any pulmonary arteries (Fig. 2). However, it showed dilatation of the pulmonary trunk (31.21 mm) and both pulmonary arteries (approx. 20 mm). An ultrasound examination of the deep veins of the lower extremities also did not indicate any signs of thrombosis.

The entire clinical picture in presented case, i.e. an abrupt onset of symptoms during labour, uterine atony, DIC, acute right ventricle overload in the absence of thrombi, indicated the diagnosis of amniotic fluid embolism. Therefore, it was decided to stop anticoagulation, while the conservative treatment was continued with a good clinical effect. The patient was discharged a few days later after stabilization of medical condition.

After the initial treatment with hypothermia, the newborn's condition gradually improved. Since the 9<sup>th</sup> day of his life, the child was discharged from the neonatal intensive care unit and was rooming-in with his mother and breastfed on demand. Magnetic resonance imaging of the child's central nervous system performed on the 15<sup>th</sup> day of life revealed no significant abnormalities.

Twelve months later, the patient returned for a follow-up cardiac examination. She felt very well, reported good physical capacity and denied any symptoms of heart failure. Due to the period of the COVID-19 pandemic, the patient did not have a control echocardiographic examination,

although there was no evidence from the history that significant abnormalities in cardiac imaging could be expected. In the first year of life, the child was under the care of the rehabilitation and neurological clinic. Tests performed after the age of 1 year showed the proper development of the child, without any neurological disorders.

## DISCUSSION

AFE is a rare but potentially catastrophic complication of perinatal period. It may occur during pregnancy, medical procedures such as amniocentesis, induction of labour, vaginal delivery, cesarean section or postpartum [4, 10]. The incidence of the disease is estimated at 1,9-8 per 100,000 pregnancies [4-8, 10-15]. It is characterized by poor maternal outcome with high fatality rate ranged from 20% to 60%, depending on country's level of development and the timing of the data [8, 10, 15]. Older data indicate a mortality reaching even about 90% [4, 7]. AFE is an uncommon disease, but it causes up to 10% of all maternal deaths [12].

The main risk factors for AFE include: advanced maternal age, multiparity, intrauterine fetal death, polyhydramnios, placental abnormalities, gestational diabetes, trauma and obstetric interventions such as induction of labour, instrumental vaginal delivery and cesarean delivery [4, 7, 11, 13, 14]. It should be emphasized that our patient did not have any of them – a young woman in her first pregnancy, with no complications and normal spontaneous delivery before deterioration of medical condition. Currently, the disease remains unpredictable and unpreventable. Further research is needed to understand the processes that predispose some patients to the development of AFE.



Moreover, the diagnosis of AFE is very difficult, and the complication itself resembles other causes of the rapid deterioration of woman's condition that may occur in the perinatal period, such as: acute pulmonary embolism by thrombus, anaphylaxis, cardiogenic shock, sepsis, air embolism or side effects of anesthetics [10, 15]. To accelerate and facilitate the diagnosis of AFE, Society for Maternal-Fetal Medicine (SMFM) and Amniotic Fluid Embolism Foundation have recently proposed four diagnostic criteria: (1) sudden cardiac arrest or cardio-respiratory collapse, (2) clinical onset during labour or within half an hour of placental delivery, (3) DIC and (4) absence of fever ( $\geq 38^{\circ}\text{C}$ ) during labour [4, 12, 16]. Our patient had all of the above features. In most of the differential diagnoses, these criteria do not occur simultaneously. However, the research also shows that less than a half of women with AFE confirmed, presented them all [12]. Therefore, the diagnosis can only be made by excluding other possibilities [5, 10].

Other diagnostic methods, such as the detection of tissue elements from the amniotic fluid in blood samples taken during pulmonary catheterization, in sputum or in lung histopathological examination, are characterized by low diagnostic value, especially at the onset of symptoms. What is important, they do not form embolic material as a physical obstruction closing pulmonary arteries. The development of acute right ventricle overload is caused by the vasoconstrictor effect of amniotic fluid components [7].

In the presented case, first of all, there were features of acute overload of the right heart and pulmonary arteries, requiring differentiation from pulmonary embolism caused by thrombus. Therefore, anticoagulation was temporarily initiated and then stopped immediately after receiving pulmonary angiogram.

It cannot be excluded that the reaction cascade was initiated by respiratory depression following intrathecal administration of the anesthetics. Caesarean section, in particular traumatic, is one of the few recognized risk factors for AFE. Nevertheless, the intraoperative bleeding indicates that amniotic fluid entered the patient's circulatory system earlier and contributed to the development of DIC.

In such clinical cases, early diagnosis and an immediate multidisciplinary response are essential to improve survival of both mother and baby. Unfortunately, due to the rarity of AFE, health professionals do not have the appropriate experience to effectively treat this obstetric complication. The proper medical treatment is based on emergency cesarean delivery, cardiopulmonary stabilization and maintenance of homeostasis [11, 15]. To facilitate medical care, this year the SMSF proposed general guidance in the form of an AFE checklist for initial management [15]. Implementing these guidelines along with running simulations can significantly improve outcomes.

## CONCLUSIONS

The clinical picture of emergencies in the perinatal period is not very specific, but the sudden deterioration of patient's condition at that time requires extensive diagnostics and decisive treatment. AFE is diagnostically challenging disease with high fatality rate. The diagnosis is based on clinical symptoms and the exclusion of other identified

causes. Despite improving medical care, AFE is still one of the main causes of maternal deaths in developed countries. This shows how great is the need for further research, particularly in the prevention of AFE.

## REFERENCES

- Ouzounian JG, Elkayam U. Physiologic changes during normal pregnancy and delivery. *Cardiol Clin*. 2012;30(3):317–329. doi: 10.1016/j.ccl.2012.05.004.
- Kuhn JC, Falk RS, Langesæter E. Haemodynamic changes during labour: continuous minimally invasive monitoring in 20 healthy parturients. *Int J Obstet Anesth*. 2017;31:74–83. doi: 10.1016/j.ijoa.2017.03.003.
- Cohen WR, Friedman EA. The assessment of labor: a brief history. *J Perinat Med*. 2018;46(1):1–8. doi: 10.1515/jpm-2017-0018.
- Durgam S, Sharma M, Dadhwal R et al. The role of extra corporeal membrane oxygenation in amniotic fluid embolism: a case report and literature review. *Cureus*. 2021;13(2):e13566. doi: 10.7759/cureus.13566.
- Sultan P, Seligman K, Carvalho B. Amniotic fluid embolism: update and review. *Curr Opin Anaesthesiol*. 2016;29(3):288–96. doi: 10.1097/aco.0000000000000328.
- Baldisseri MR, Clark SL. Amniotic fluid embolism. [www.uptodate.com](http://www.uptodate.com), literature review current through: Mar 2021, topic last updated: Apr 02, 2020. [download 14.04.2021]; <https://www-1uptodate-1com-100022cgl02e8.han3.wum.edu.pl/contents/amniotic-fluid-embolism>
- Koziółek AH, Gaca M, Szymanowski KS et al. Koagulopatia ze zużycia jako wiodący objaw zatoru płynem owodniowym – opis przypadku. *Ginekol Pol*. 2016;87(2):153–6. doi: 10.17772/gp/57808.
- Shen F, Wang L, Yang W et al. From appearance to essence: 10 years review of atypical amniotic fluid embolism. *Arch Gynecol Obstet*. 2016;293(2):329–34. doi: 10.1007/s00404-015-3785-z.
- Yang RL, Lang MZ, Li H, et al. Immune storm and coagulation storm in the pathogenesis of amniotic fluid embolism. *Eur Rev Med Pharmacol Sci*. 2021;25(4):1796–1803. doi: 10.26355/eurrev\_202102\_25073.
- Sitaula S, Das D, Sitaula S, et al. Amniotic fluid embolism: A rare cause of maternal collapse—A case report. *Clin Case Rep*. 2020;8(12):3359–3361. doi: 10.1002/ccr3.3433.
- Lisonkova S, Kramer MS. Amniotic fluid embolism: A puzzling and dangerous obstetric problem. *PLoS Med*. 2019;16(11):e1002976. doi: 10.1371/journal.pmed.1002976.
- Ponzio-Klijanienko A, Vincent-Rohfritsch A, Girault A et al. Evaluation of the 4 diagnosis criteria proposed by the SMFM and the AFE foundation for amniotic fluid embolism in a monocentric population. *J Gynecol Obstet Hum Reprod*. 2020;49(9):101821. doi: 10.1016/j.jogoh.2020.101821.
- Haftel A, Chowdhury YS. Amniotic Fluid Embolism. *StatPearls Publishing* (online) 2020 Nov [download 14.04.2021]; <https://www.ncbi.nlm.nih.gov/books/NBK559107/>
- Fitzpatrick KE, van den Akker T, Bloemenkamp KWM et al. Risk factors, management, and outcomes of amniotic fluid embolism: A multicountry, population-based cohort and nested case-control study. *PLoS Med*. 2019;16(11):e1002962. doi: 10.1371/journal.pmed.1002962.
- Combs CA, Montgomery DM, Toner LE et al. Society for Maternal-Fetal Medicine Special Statement: Checklist for initial management of amniotic fluid embolism. *Am J Obstet Gynecol*. 2021;224(4):B29–B32. doi: 10.1016/j.ajog.2021.01.001.
- Clark SL, Romero R, Dildy GA et al. Proposed diagnostic criteria for the case definition of amniotic fluid embolism in research studies. *Am J Obstet Gynecol*. 2016;215(4):408–12. doi: 10.1016/j.ajog.2016.06.037.

**ORCID and contributionship:**

Mateusz Jermakow: 0000-0002-2438-9677 <sup>A,D</sup>

Agnieszka Palus: 0000-0003-1430-8260 <sup>A,D</sup>

Michał Ciurzyński: 0000-0001-8393-5415 <sup>B,E</sup>

Bronisława Pietrzak: 0000-0002-9192-3323 <sup>B,E</sup>

Katarzyna Kurnicka: 0000-0001-8278-7924 <sup>B</sup>

Piotr Pruszczyk: 0000-0002-9768-0000 <sup>B</sup>

Piotr Bienias: 0000-0003-3567-338X <sup>A,F</sup>

**Conflict of interest:**

*The Authors declare no conflict of interest.*

---

**CORRESPONDING AUTHOR**

**Piotr Bienias**

Department of Internal Medicine and Cardiology,

Medical University of Warsaw, Poland

Lindleya 4, 02-005, Warsaw, Poland

tel. +48604405365

e-mail: pbienias@mp.pl

**Received:** 09.05.2021

**Accepted:** 30.07.2021

---

A – Work concept and design, B – Data collection and analysis, C – Responsibility for statistical analysis,  
D – Writing the article, E – Critical review, F – Final approval of the article